

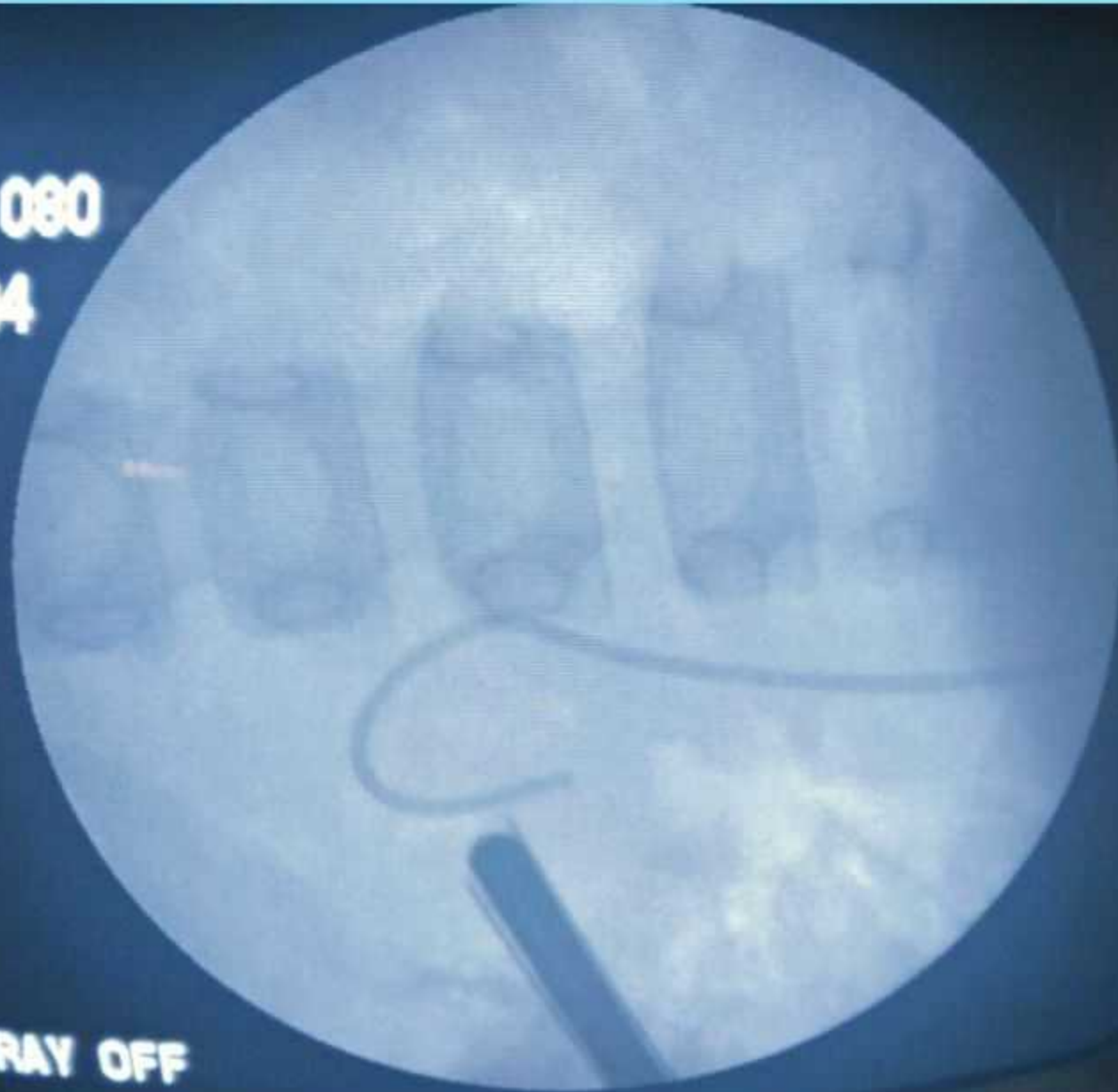


PARUL SEVASHRAM HOSPITAL

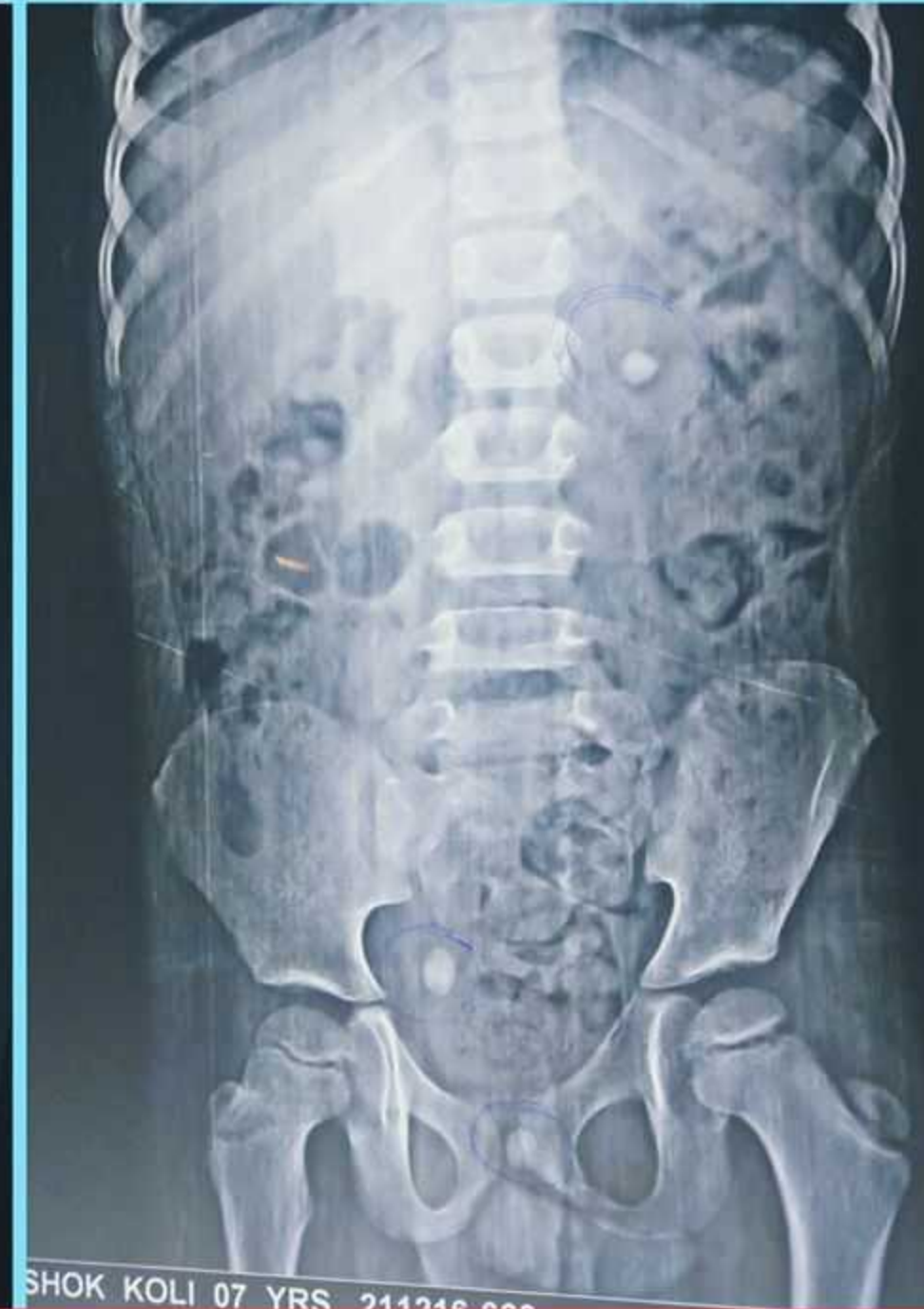Horizon from a Healthy Today to a Healthier Tomorrow

#PSHSuccessStories

LIH
ROTN:080
AVG:04



X-RAY OFF



SHOK KOLI 07 YRS 211218 000

7 yr old male child presented with urinary retention & altered renal function having Bladder stone, Rt Lower uretic stone & Lt renal pelvic stone. Surgery was done in two stage, cystolithotripsy+ rt Ureterorenoscopy with B/L DJ stent followed by Lt PCNL.