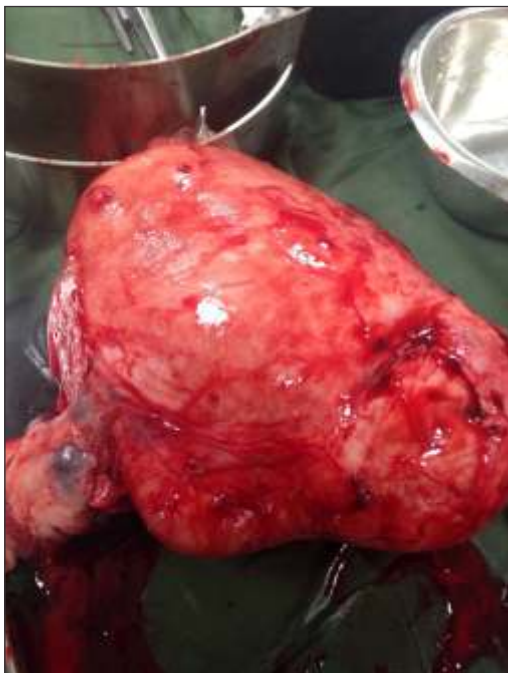


Patient Name		D.O.A.	07/12/2015
Age/Gender	46/F	D.O.D.	
Address		Department	OBGY
Treating Doctors	Dr. C. R. Kakani, J. T. Gohil, Dr. Neha Nimbark		
Diagnosis	Fibroid Uterus		

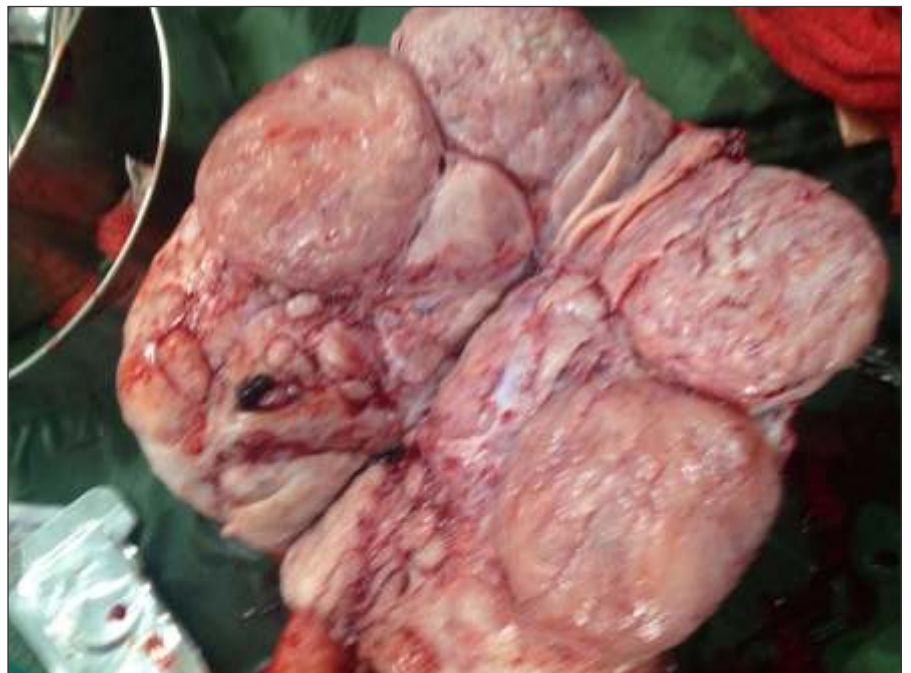### SUMMARY (CLINICAL):

A 46 yr Lady came with large swelling per abdomen with heavy mensruation. She had completed her family. It was diagnosed case of Uterine (Fundal) Myometrial Fibroid. Total abdominal hystrectomy was done & the fibroid which weighed 2.7 kgs was removed.

Patient had a uneventful stay in the hospital and discharged on 5th post-operative day.



fibroid at the fundus of Uterus



fibroid at the fundus of Uterus - on cut section