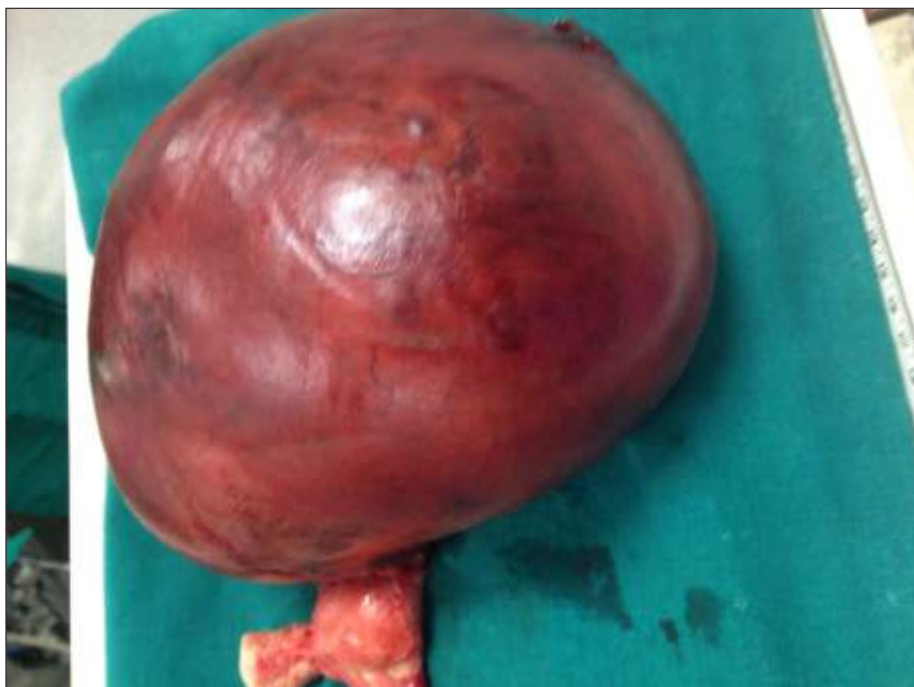


Patient Name		D.O.A.	16/11/2015
Age/Gender	42/F	D.O.D.	
Address		Department	OBGY
Treating Doctors	Dr. Kakani, J. T. Gohil, Dr. Neha Nimbark		
Diagnosis	Ovarian Cyst		

SUMMARY (CLINICAL):

A 42 yr Female came with lump in abdomen since 5 years. She had completed her family. USG & CT Scan studies showed a large ovarian cyst. Laprotomy was done cyst weighing 3.5 kg was removed followed by Hysterectomy. Histopathological examination reports suggested benign ovarian cyst. Patient was discharged uneventfully after 6th post-operative day.



Ovarian Cyst - Gross