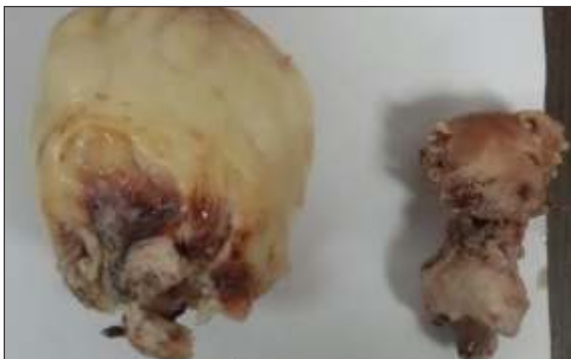


Patient Name	Naina	D.O.A.	8th March 2016
Age/Gender	42/F	D.O.D.	-
Address		Department	OBGY
Treating Doctors	J. T. Gohil, Dr. C. R. Kakani, Dr. Neha Nimbark		
Diagnosis	Cervical Fibroid		

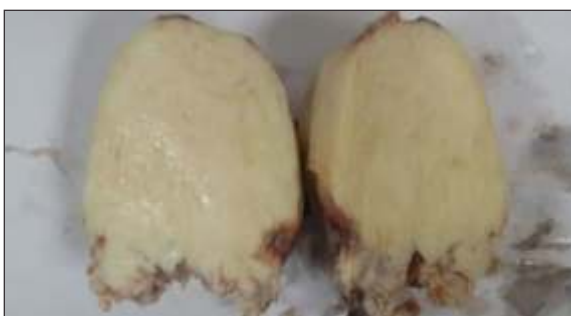SUMMARY (CLINICAL):

A 42 yr Female came with foul smelling discharge and bleeding per vaginally with Haemoglobin- 6.0 gm. On examination she had a large cervical fibroid of size 15X 13 cms. She had previously on LSCS.

On laprotomy hysterectomy and removal of cervical fibroid was done which was sent for histopathology examination. 2 units of PCV pre-operatively and 1 unit PCV post operatively was given. Patient was stable and had an uneventful stay in the hospital

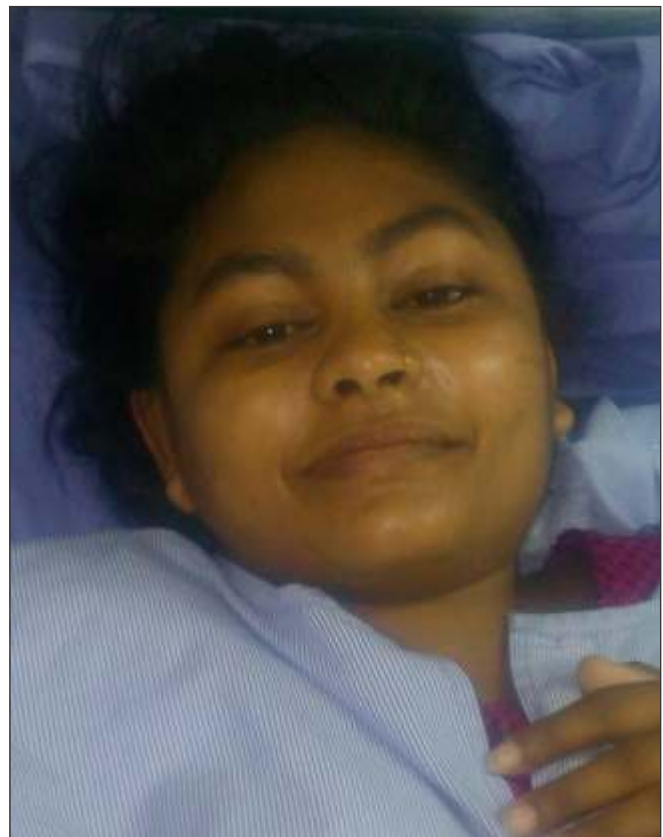

L - Huge cervical fibroid
R - Uterus with Adnexa



cervical fibroid on Cut Section

Before Treatment



After Treatment